

# Centennial Review

## Clinical Advances in the Diagnosis and Therapy of the Interstitial Lung Diseases

Talmadge E. King, Jr.

Department of Medicine, Division of Pulmonary and Critical Care Medicine, San Francisco General Hospital, University of California–San Francisco, San Francisco, California

The last century experienced remarkable advances in the classification, diagnosis, and understanding of the pathogenesis of the interstitial lung diseases. Technological advances, particularly physiologic testing, lung imaging studies, bronchoalveolar lavage, surgical lung biopsy, and histopathologic assessment, improved our understanding of these entities. In particular, the advent of high-resolution computed tomography, the narrowed pathologic definition of usual interstitial pneumonia, and recognition of the prognostic importance of separating usual interstitial pneumonia from other idiopathic interstitial pneumonia patterns have profoundly changed the approach to these processes. Most recently, genetic medicine, the use of new technologies (e.g., microarrays, mass spectroscopic analysis of proteins, and laser capture microdissection), and the development of animal models have had a major impact on understanding the pathogenesis and potential molecular targets for interfering with fibrogenesis. This article highlights some of the advances and changes in clinical practice that took place in the management of patients with interstitial lung diseases over the last century.

**Keywords:** high-resolution computed tomography; idiopathic pulmonary fibrosis; interstitial lung diseases; usual interstitial pneumonia; non-specific interstitial pneumonia; physiology; sarcoidosis

The interstitial lung diseases (ILDs), also called diffuse parenchymal lung diseases, are a diverse group of pulmonary disorders classified together because of similar clinical, roentgenographic, physiologic, or pathologic features. By the beginning of the 20th century, the gross and microscopic pathology of chronic ILD was well described. The focus turned to identifying occupational or environmental causes of ILD. Efforts from around 1950 to 1970 were aimed at understanding the radiographic, physiologic, and pathologic features of these diseases. By the 1960s, progress in categorizing ILDs was made: connective tissue diseases, drugs, occupational and environmental exposures, sarcoidosis, and inherited conditions were recognized as distinct entities. Those conditions that either remained unassociated with another process or without a clear cause were often lumped together under a single heading (e.g., “Hamman-Rich syndrome,” “fibrosing alveolitis,” or “idiopathic pulmonary fibrosis” [IPF]).

Because the topic of ILD is vast, the themes chosen for discussion represent some editorial bias toward those that we have found most interesting or consider important to current practice or future studies in this field. Because of space limita-

tions, we have not provided a complete list of references or discussed some entities where important advances have been made. Topics not discussed include the following: familial lung fibrosis (1), connective tissue diseases (2), pulmonary vasculitis (3, 4), pulmonary alveolar proteinosis (5), eosinophilic pneumonias (6), diffuse alveolar hemorrhage (7), pulmonary Langerhans’ cell histiocytosis (8), lymphocytic interstitial pneumonia (3, 4), and drug-induced lung disease (9).

### EPIDEMIOLOGY OF ILDs

Epidemiologic studies have been critical in our recognition of causes and establishing links between environmental and occupational exposure and the risk of developing ILD (*see below*). However, it has only been over the last two decades that the scope of investigation has expanded to include studies on the occurrence, risk factors, and prognosis of lung fibrosis (10). During the latter half of the 20th century, epidemiologic data disclosed epidemiologic features that have enabled us to construct environmental and host factors that appear to play roles in the development of ILD (Table 1). Unfortunately, the study of the epidemiology of ILD remains problematic for several reasons, including the following: (1) insufficient number of cases to have adequate statistical power to assess the role of chance; (2) sampling bias because referral centers do not see cases representative of the general population; (3) lack of a precise, consistent case definition; (4) variable methods of case ascertainment; (5) variability in disease presentation; (6) lack of sensitive and specific diagnostic tests, resulting in underrecognition and misdiagnosis of the disease; (7) requirement for surgical lung biopsy for definitive diagnosis; and (8) the paucity of systematic epidemiologic investigations of cause (10, 11). Nonetheless, largely by use of the case-control study design, considerable progress has been made in the epidemiologic investigation of these entities (10). For example, a population-based registry in New Mexico examined for the prevalence and incidence of ILD. They showed that the prevalence was 80.9 per 100,000 in males and 67.2 per 100,000 in females, corresponding with annual incidence rates of 31.5 per 100,000/year in males and 26.1 per 100,000/year in females (Table 2) (10). The prevalence has been shown to increase with age.

### DIAGNOSIS OF ILDs

The patient with suspected interstitial pneumonia presents a formidable diagnostic challenge to physicians. Remarkable advances in technology have improved our diagnostic accuracy and fueled our understanding of the ILDs. A complete review of these important advances is beyond the scope of this article (3, 4). However, we will highlight the important roles that physiologic testing, surgical lung biopsy, fiberoptic bronchoscopy with bronchoalveolar lavage (BAL), and high-resolution computed tomography (HRCT) scanning have played in improving our understanding of these disease processes.

(Received in original form March 29, 2005; accepted in final form April 29, 2005)

Correspondence and requests for reprints should be addressed to Talmadge E. King, Jr., M.D., San Francisco General Hospital, Room 5H22, 1001 Potrero Avenue, San Francisco, CA 94110. E-mail: tking@medsfgh.ucsf.edu

Am J Respir Crit Care Med Vol 172, pp 268–279, 2005  
Originally Published in Press as DOI: 10.1164/rccm.200503-483OE on May 5, 2005  
Internet address: www.atsjournals.org

**TABLE 1. EPIDEMIOLOGIC FINDINGS ASSOCIATED WITH SARCOIDOSIS AND IDIOPATHIC PULMONARY FIBROSIS**

	Sarcoidosis	Idiopathic Pulmonary Fibrosis
Host-related findings	Age (young)	Age (old)
	Sex (women)	Sex (men)
	Familial clustering	Familial clustering
	Race	Chronic aspiration (silent)
Time and space-related findings	Exposures	Exposures
	Positive associations	Positive associations
	Agricultural employment	Metal dust
	Insecticides (work)	Wood dust
	Pesticides (work)	Livestock
	Mold/mildew	Farming/agricultural area
	Musty odors	Textile dust
	Negative associations	Stone/sand
	Wood dust	Smoking
	Pine pollen	Wood fires
	Metals	
	Silica or talc	
	Health care work	
	Geographical variation	
	Local clustering	
	Climate and seasonal clustering	
	Migration	
Time-space clustering		

Data are from References 10, 91, and 92.

**Physiologic Testing**

Assessment of ventilatory function and gas exchange is essential in the evaluation of patients with ILD. In the 1950s, it was determined that the “classic” physiologic response in patients with ILDs was a restrictive pattern and/or impaired gas exchange. In addition, careful evaluation showed that many ILDs are associated with an obstructive pattern because of their bronchiolocentric propensity. These ILDs include sarcoidosis, hypersensitivity pneumonitis (HP), eosinophilic granuloma, lymphangioleiomyomatosis (LAM), tuberosus sclerosis, and neurofibromatosis. Subsequently, investigators examined many other important issues: correlation between structure and function, role in assessing disease severity, correlation with radiographic changes, usefulness in following the clinical course and response to therapy, and the impact of smoking.

An important controversy that physiologic testing helped resolve was the mechanism of the hypoxemia in ILD. Initially, an anatomic barrier to oxygen caused by a thickened alveolar interstitium (“alveolar-capillary block”) was suspected (12).

Later, ventilation-perfusion mismatching was identified as the major factor (13) and that a diffusion barrier to oxygen was only important during exercise (14).

Because lung function studies are used to monitor and follow disease course, it was important to determine which physiologic studies best correlated with the histologic features identified on lung biopsy. In general, neither lung function nor exercise testing discriminated between fibrosis and inflammation (15–17). Smoking was shown to have a significant impact on both histopathology and lung function (17, 18). Unfortunately, lung function studies have been shown to have a limited role in predicting prognosis and responsiveness to therapy (see below). However, serial measurements in an individual patient are invaluable in determining disease progression or response to therapy.

**Open Lung Biopsy**

Open lung biopsy via thoracotomy was popularized in the 1960s (19). Before this time, transbronchial biopsy via a rigid bronchoscope or needle biopsies were used. These procedures yielded small tissue samples and were not useful in allowing recognition of the pattern of injury. Conversely, open lung biopsy was shown to have a very high diagnostic yield (92%) and a low morbidity and mortality (2.5 and 0.3%, respectively). The introduction of video-assisted thoracoscopic surgery increased the use of surgical lung biopsy. Video-assisted thoracoscopic surgery had an equivalent diagnostic accuracy, morbidity, and length of hospitalization compared with limited thoracotomy (20). Surgical lung biopsy remains the investigation with the greatest overall diagnostic sensitivity for ILDs. Many clinicians remain reluctant to subject their patients to surgical lung biopsy, likely reflecting their pessimism that findings on lung biopsy will alter the proposed treatment plan. Consequently, surgical lung biopsy continues to be underused. Importantly, recent studies show that this lack of use of surgical lung biopsy is not justified. Experts in the field could only make a confident clinical diagnosis of IPF in approximately 50% of patients subsequently confirmed by biopsy to have IPF, even when the cases studied had been culled of other diffuse lung diseases (e.g., those with occupational exposure

**TABLE 2. PREVALENCE AND INCIDENCE (PER 100,000) OF INTERSTITIAL LUNG DISEASES BY SEX**

Diagnosis	Prevalence		Incidence	
	Men	Women	Men	Women
Pulmonary fibrosis*	32.1	30.3	16.4	12.9
Connective tissue diseases	7.1	11.6	2.1	3.0
Occupational and environmental	20.8	0.6	6.2	0.8
Sarcoidosis	8.3	8.8	0.9	3.6
Drug and radiation	1.2	2.2	1.8	1.1
Pulmonary hemorrhage syndromes	0.6	2.2	1.5	0.8
Other	10.7	11.6	2.7	3.9
Total	80.9	67.2	31.5	26.1

Cases are from Bernalillo County, New Mexico, October 1, 1988, to September 30, 1990. Adapted by permission from Reference 10.

\* Includes cases coded as idiopathic pulmonary fibrosis, pulmonary fibrosis, and interstitial pneumonitis.

or associated with connective tissue disease). In addition, in a multidisciplinary study, histopathologic information had the greatest impact on the final diagnosis (compared with HRCT and clinical data), especially when the initial clinical/radiographic diagnosis was not IPF (21).

Importantly, histopathologic evaluation has become the basis for the classification of the idiopathic interstitial pneumonias (IIPs), and it has been shown that the morphologic patterns provide important prognostic information that can guide therapy (see below) (22). Several technical issues have been resolved:

1. Site of the biopsy: this should be obtained at the edge of the grossly abnormal areas of the lung to include grossly normal lung parenchyma and avoid the radiologically or grossly palpable "worst" areas and not the tips of the lingula and right middle lobe
2. Number of biopsies: more than one lobe of the lung
3. Size of specimens: the biopsy must be deep, extending well into the subpleural lung parenchyma (~3–5 cm in greatest dimension) (4)

### Transbronchial Lung Biopsy

The introduction of the flexible fiberoptic bronchoscope and transbronchial biopsy was heralded as a useful "minimally invasive" method to obtain tissue, with a marked reduction in morbidity compared with surgical lung biopsy. These biopsies, though quite small, often yielded adequate amounts of lung tissue that could be used in the diagnosis of many lung diseases (e.g., sarcoidosis, malignancy, or infection). Initial reports claimed yields in ILD of 70 to 80% (23, 24). However, it was soon shown that the accuracy of transbronchial biopsy was only 7 to 37% in immunocompetent hosts (24–27). Using transbronchial biopsies to diagnose IIP is not recommended (22, 28).

### BAL

The technique of BAL via the fiberoptic bronchoscope revolutionized the scientific and clinical investigation of lung disorders (29). BAL permitted the recovery of cells from the airway and alveolar space and of soluble substances from the extracellular lining fluid. This tool has provided important insights into local host immunity, inflammation, fibrogenesis, and infections (30).

It was soon believed that BAL would supplant other more invasive procedures and could be used in the longitudinal monitoring of disease activity in patients with ILD. In fact, the analysis of BAL seemed to indicate that certain cellular profiles correlated with several processes: for example, sarcoidosis has a lymphocytosis characterized by an increased in T-helper cells and a high CD4/CD8 ratio; HP has a marked T lymphocytosis, especially the suppressor subset CD8; and IPF is characterized by increases in neutrophils and eosinophils. Unfortunately, in the IIPs, BAL findings have limited clinical utility either as an aid to diagnosis, as a prognostic indicator, or as a guide to therapy (29).

### Chest Imaging Studies

**Chest radiograph.** The chest radiograph can be useful to evaluate for general patterns of disease distribution (upper vs. lower lobe involvement, alveolar filling vs. interstitial opacities) and in the identification of other useful findings that might aid in differential diagnosis, including pleural abnormalities, cardiomegaly, and lymphadenopathy. Despite the important role of the chest radiograph in the initial detection and evaluation of lung disease, it lacks diagnostic specificity and sensitivity in ILDs (22, 28). In addition, the chest radiograph correlates poorly with the histologic pattern, the anatomic distribution of disease, and the physiologic severity of disease (with the exception of honeycombing).

**HRCT scanning.** Since its introduction in the 1980s, HRCT

scanning, with its greater ability to visualize fine detail within the lung, has replaced conventional chest radiography as the preferred imaging method for the ILDs. The characteristic radiographic features of many ILDs (especially for IPF) and correlations of these features with histopathology have been described (Table 3) (22, 28, 31). HRCT has been found useful in the evaluation of ILDs in the following areas: identification of the presence of disease (often being abnormal when other studies are normal or only mildly impaired), evaluation of the extent of disease, characterization of the patterns of the disease, narrowing the differential diagnosis, as a guide to the site of biopsy, and assessing the clinical course of the disease and response to therapy. Unfortunately, because of the lack of diagnostic specificity in most settings, HRCT has not replaced the need for histologic confirmation in most patients with ILD (21, 32, 33).

### Other Imaging Techniques

Several other techniques have not lived up to expectations and to date have no well-documented clinical role in the diagnosis, management, or prognosis of most diffuse lung processes. These include the following (34): magnetic resonance imaging, gallium 67 citrate scanning, positron emission tomography, and technetium 99m-diethylenetriamine penta-acetate scanning.

### IIPs

#### Histopathologic Classification

In 1944, Hamman and Rich (35) described four cases of rapidly progressive, fatal, diffuse interstitial fibrosis (Figure 1). Thereafter, it was widely accepted that the morphologic features of diffuse idiopathic fibrotic lung disease was "a diffuse interstitial fibrosis with mononuclear cell infiltration" (termed "Hamman-Rich syndrome"). In the 1960s, after the increased use of surgical lung biopsy and the availability of lung specimens in earlier stages of the disease process, it was pointed out that the spectrum of histopathologic findings was much broader and included intra-alveolar, interstitial, and airway changes (36–38).

In 1964, Scadding introduced the term "diffuse fibrosing alveolitis" to encompass the features of both interstitial and intra-alveolar changes in the ILDs. Subsequently, Scadding reported a classification of pulmonary fibrosis that was divided into two groups: all those diseases that were at that time defined etiologically (e.g., asbestosis, silicosis, HP, drugs, infections) and those conditions of unknown cause that were defined histopathologically (39). This second group was further subdivided into conditions that are part of a systemic disease (e.g., sarcoidosis) or fibrosing alveolitis (defined as pulmonary disease only). Scadding added that, if no etiology is known, the term "cryptogenic" or the phrase "of unknown cause" could be added to the term "fibrosing alveolitis."

In 1969, Liebow and Carrington (38) described five histopathologic subgroups of chronic IIP based on specific histologic criteria: undifferentiated or "usual" interstitial pneumonia (UIP), bronchiolitis interstitial pneumonia, desquamative interstitial pneumonia (DIP), lymphoid interstitial pneumonia, and giant cell interstitial pneumonia. Liebow and Carrington proposed that histopathologic classification might help to distinguish clinically distinct conditions, and correlate with the radiographic appearance, clinical course, and prognosis (38).

Several controversies between the British and American investigators existed: (1) the terminology (e.g., "interstitial," "pneumonia," "alveolitis," "idiopathic," "cryptogenic") and (2) the meaning of the "desquamative" pattern (i.e., the British school believed the desquamative pattern was a stage of the usual pattern, whereas the American school believed DIP was a separate entity from UIP). In retrospect, there were little differences

**TABLE 3. CLINICAL, RADIOLOGIC, AND HISTOLOGIC FEATURES, TREATMENT AND PROGNOSIS OF THE IDIOPATHIC INTERSTITIAL PNEUMONIAS**

Clinical-Radiographic-Pathologic Diagnosis	IPF	NSIP	COP	AIP	DIP, RB-ILD	LIP
Duration of illness	Chronic (> 12 mo)	Subacute to chronic (months to years)	Subacute (< 3 mo)	Abrupt (1–2 wk)	Subacute (weeks to months), smoker	Chronic (> 12 mo), women
Frequency of diagnosis	47–64%	14–36%	4–12%	Rare (< 2%)	10–17%	Rare
HRCT	Peripheral, subpleural, basal predominance	Peripheral, subpleural, basal, symmetric	Subpleural or peribronchial	Diffuse, bilateral	DIP: Diffuse ground-glass opacity in the middle and lower lung zones RB-ILD: Bronchial wall thickening, centrilobular nodules, patchy ground-glass opacity	Diffuse
	Reticular opacities	Ground-glass attenuation	Patchy consolidation	Ground-glass opacities, often with lobular sparing		Centrilobular nodules
	Honeycombing	Consolidation (uncommon)	Nodules			Ground-glass attenuation
	Traction bronchiectasis/bronchiolectasis	Lower lobe volume loss				Septal and bronchovascular thickening
	Architectural distortion	Subpleural sparing may be seen				Thin-walled cysts
	Focal ground glass (rare)					
Histologic patterns	Usual interstitial pneumonia	NSIP	Organizing pneumonia	Diffuse alveolar damage	DIP RB-ILD	LIP
Treatment	Poor response to corticosteroid or cytotoxic agents	Corticosteroid responsiveness	Corticosteroid responsiveness	Effectiveness of corticosteroid unknown	Smoking cessation Corticosteroid responsiveness	Corticosteroid responsiveness
Prognosis	50–80% mortality in 5 yr	Unclear, < 10% mortality in 5 yr	Deaths rare	60% mortality in < 6 mo	5% mortality in 5 yr	Not well defined

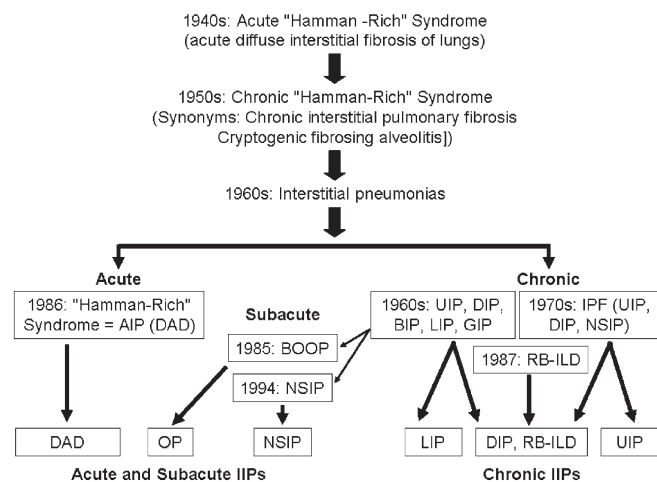
*Definition of abbreviations:* AIP = acute interstitial pneumonia; COP = cryptogenic organizing pneumonia; DIP = desquamative interstitial pneumonia; HRCT = high-resolution computed tomography; IPF = idiopathic pulmonary fibrosis; LIP = lymphocytic interstitial pneumonia; NSIP = nonspecific interstitial pneumonia; RB-ILD = respiratory bronchiolitis–associated interstitial lung disease.

between the two schools of thought and they complemented each other rather than identified fundamental differences. For example, Liebow and Carrington’s description of histopathologic subgroups of chronic IIP was essentially a subdivision of Scad-

ding’s fibrosing alveolitis. For many years, clinicians abandoned the designations DIP and UIP, believing that they represented stages in the development of IPF, or worse, were simply “cryptic,” “outmoded,” “imprecise,” and “ambiguous” labels (40, 41).

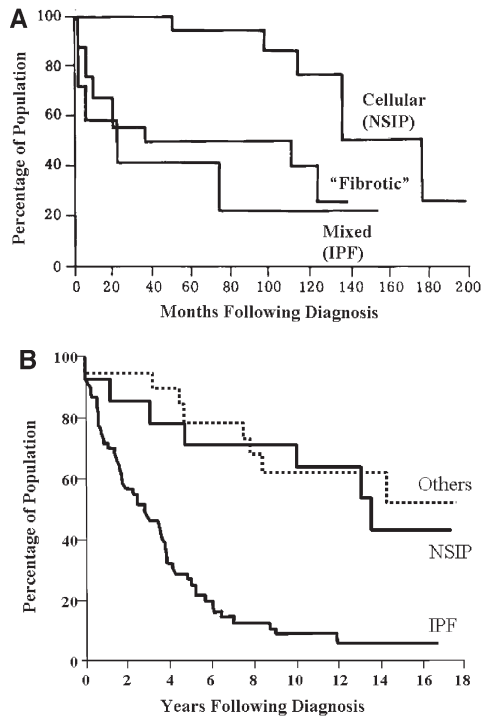
In 1998, Katzenstein and Myers (41) revised the classification scheme to include four histopathologically distinct subgroups: UIP, DIP and a closely related pattern termed “respiratory bronchiolitis–associated interstitial lung disease” (RB-ILD), acute interstitial pneumonia (formerly Hamman-Rich syndrome), and nonspecific interstitial pneumonia (NSIP). Liebow and Carrington’s lymphoid interstitial pneumonia and giant cell interstitial pneumonia subgroups were excluded because lymphoid interstitial pneumonia is a lymphoproliferative condition and giant cell interstitial pneumonia is a hard-metal pneumoconiosis. Bronchiolitis interstitial pneumonia, also known as bronchiolitis obliterans organizing pneumonia, was excluded because it was a predominantly intraluminal process. Katzenstein and Myers’ method of histopathologic categorization emphasized the need for consistent pathologic criteria for diagnosis and incorporated several key distinguishing features: the temporal heterogeneity of inflammation and fibrosis, the extent of inflammation, the extent of fibroblastic proliferation, the extent of accumulation of intraalveolar macrophages, and the presence of honeycombing or hyaline membranes. These histologic subsets have been proven to have prognostic significance (Figure 2).

In 2001, an American Thoracic Society (ATS)/European Respiratory Society (ERS) consensus panel revised Katzenstein and Myers’ classification schema to emphasize the importance of an integrated clinical, radiologic, and pathologic approach to the diagnosis of IIP (22). In addition, they concluded that the IIPs comprised a number of clinicopathologic entities, which were sufficiently different from one another to be designated as separate disease entities.



**Figure 1.** Historical progression of the classification of the idiopathic interstitial pneumonias (see text for details). Adapted by permission from References 87 and 88. AIP = acute interstitial pneumonia; BOOP = bronchiolitis obliterans organizing pneumonia; DAD = diffuse alveolar damage; DIP = desquamative interstitial pneumonia; GIP = giant cell interstitial pneumonia; IPF = idiopathic pulmonary fibrosis; LIP = lymphocytic interstitial pneumonia; NSIP = nonspecific interstitial pneumonia; OP = organizing pneumonia; RB-ILD = respiratory bronchiolitis interstitial lung disease; UIP = usual interstitial pneumonia.





**Figure 2.** (A) Survival curves in cryptogenic fibrosing alveolitis demonstrating the influence of histologic features on prognosis ( $n = 39$ ;  $p < 0.02$ ). The "mixed" and "fibrotic" cases were described as having the UIP pattern or end-stage fibrosis (with or without honeycombing). The "cellular" cases were described as having "more cellular and less fibrotic changes" and appear very likely to have had the NSIP pattern. (Only one case in this study had the DIP pattern, and it is not known if that case is reported in the cases in this analysis.) Adapted by permission from Reference 89. (B) Survival in patients with IPF (defined as UIP pattern) compared with patients with NSIP and other diffuse parenchymal lung diseases. Patients with UIP had a significantly worse survival ( $p < 0.001$ ) compared with NSIP and others subgroups. Median survival for patients with UIP was 2.8 years. Other groups included the following: DIP ( $n = 8$ ), bronchiolitis ( $n = 4$ ), BOOP ( $n = 4$ ), RB-ILD ( $n = 2$ ), chronic eosinophilic pneumonia ( $n = 1$ ), and hypersensitivity pneumonitis ( $n = 1$ ). Adapted by permission from Reference 90.

The ATS/ERS classification combined the histopathologic pattern seen on lung biopsy (as described by Katzenstein and Myers) with clinical and radiologic information to arrive at a final diagnosis. This approach allowed for the preservation of existing histopathologic and clinical terms while precisely defining the relationship between them (Table 3). When the terms are the same for the histopathologic pattern and the clinical diagnosis (e.g., DIP), it was recommended that the pathologist use the addendum "pattern" when referring to the appearance on lung biopsy (e.g., DIP-pattern), reserving the initial term for the final diagnosis. In so doing, lung biopsy was no longer considered the gold standard for the diagnosis but was one integral part of the diagnosis. The new gold standard for the diagnosis of IIP is a combination of clinical-radiographic-pathologic features arrived at by a dynamic, integrated process among clinicians, radiologists, and pathologists (when a surgical lung biopsy is available) (Table 3) (21, 22, 32, 42).

#### IPF

**Definition.** IPF is now identified by "what it is rather than by what it is not" (22, 28, 41). To emphasize the distinct pathophysi-

ology and clinical course of IPF, the ATS/ERS has recommended reserving the term "IPF" for the clinical condition characterized by progressive dyspnea and chronic cough, restrictive lung disease, and the histopathologic pattern of UIP (22, 28). This important change emphasized the clinical relevance of histopathology, in particular UIP as defined by the ATS/ERS consensus statements (22, 28).

**UIP: a paradigm shift.** Distinguishing UIP from the other histopathologic subgroups of IIP identified important therapeutic and prognostic implications. For years, the prevailing pathophysiologic theory in ILD was that generalized inflammation eventually leads to widespread parenchymal fibrosis and progressive decline in pulmonary function. This model seems to hold true for many of the corticosteroid-responsive ILDs (e.g., DIP, RB-ILD, NSIP, HP, eosinophilic pneumonia, sarcoidosis, and organizing pneumonia), but only for a minority, if any, of patients with UIP. The historical belief that UIP represents the final common pathway for all forms of lung injury appears incorrect. Instead, with few exceptions, UIP seems to be a distinct pathophysiologic entity characterized by minimal inflammation and chronic fibroproliferation caused by abnormal parenchymal wound healing (43).

In the past, the pattern of pulmonary fibrosis associated with connective tissue diseases was said to be morphologically indistinguishable from UIP. However, retrospective studies of lung biopsies in patients with connective tissue disease using the current histopathologic criteria show that the most common pathologic pattern is NSIP (82% of subjects with connective tissue disease) and only a minority of cases show the pattern of UIP (18% of subjects with connective tissue disease; Table 4) (44–50). These findings also provide an explanation for the identification of immune complexes in patients previously diagnosed with IPF (i.e., they most likely had an autoimmune disease) (51). Furthermore, even the patients labeled as UIP in these current studies generally do not behave like patients with IPF (i.e., they have atypical clinical, radiographic, or histopathologic features, and survival is better than in IPF) (45, 48).

**Diagnosing IPF without surgical lung biopsy.** In the absence of a surgical lung biopsy, the diagnosis of IPF remains unproven (22, 28). Yet, in clinical practice, surgical lung biopsies are performed in less than 15% of patients (42). This low rate of surgical lung biopsies occurs despite the absence of evidence-based clinical, radiologic, and physiologic diagnostic criteria.

The ATS/ERS consensus statement described major and minor criteria for the clinical diagnosis of IPF developed from expert opinion (Table 5). If patients do not meet these major and minor criteria, surgical lung biopsy should be pursued. These criteria are useful and have been widely used; however, the following issues need to be addressed: (1) the diagnostic accuracy of these criteria should be examined in a prospective multicenter cohort study of patients presenting with a suspected diagnosis of IPF (preliminary data suggest that these criteria are accurate in only a subset of patients with classic HRCT features of IPF), (2) the HRCT criteria need to be better defined, and (3) there needs to be a reappraisal of the role of transbronchial lung biopsy and BAL.

**Accuracy of HRCT.** The ability of HRCT scanning to diagnose IPF has reported sensitivities of 43 to 78% and specificities of 90 to 97% for confident radiographic diagnosis (21, 32, 52–54). These studies argue that when the clinical and radiographic diagnoses are consistent, IPF can be confidently diagnosed. Importantly, they also demonstrate that this consistency is only present in about half of patients with biopsy-confirmed UIP. Furthermore, an HRCT pattern consistent with a confident diagnosis of IPF represents mid- to late-stage disease and is associated with a particularly ominous prognosis (55). Finally, some caution is required because prospective data on the diagnostic

TABLE 4. HISTOPATHOLOGIC SUBSETS IN CONNECTIVE TISSUE DISEASE

Pathologic Feature	Total (n = 177)	Systemic Sclerosis* (n = 102)	Rheumatoid Arthritis† (n = 24)	Polymyositis-Dermatomyositis‡ (n = 51)
NSIP	146 (82%)	83	17	46
UIP	31 (18%)	19	7	5

Definition of abbreviations: NSIP = nonspecific interstitial pneumonia; UIP = usual interstitial pneumonia.

\* Data from References 45–48.

† Data from References 48, 49.

‡ Data from References 44, 47, 49, 50.

accuracy of HRCT scans in unselected populations are still lacking.

**Clinical course of IPF.** The clinical course of IPF is variable; however, the long-term survival in IPF is distinctly poor (see Figure 2). Data from a large clinical trial suggest that a large proportion of patients with mild-to-moderate IPF remain stable for prolonged periods, whereas others experience an accelerated phase, with a rapid decline and subsequent death (56, 57). It is increasingly apparent that “acute exacerbations” or an “accelerated phase of rapid clinical decline” characterizes the clinical course of IPF and portends a poor prognosis (Figure 3). Histologic examination of the lung has shown a pattern of acute lung injury (diffuse alveolar damage) on the background of UIP (58, 59). Better understanding and management of these episodes appear critical to reducing the death rate in IPF.

**Predictors of survival in IPF/UIP.** A number of features measured at the time of diagnosis have been identified to be predictors of worse survival in IPF as follows: increasing age; male sex; smoking history (higher the number of pack-years, the worse the prognosis); degree of dyspnea, severity of lung function, and gas exchange at rest and with exercise; degree of radiographic abnormality; neutrophilia or eosinophilia on cellular analysis on BAL; decreased surfactant protein (SP)-A content and SP-A/phospholipid ratio; honeycomb changes on HRCT scan; and extent and severity of the fibroblastic foci on lung biopsy (60–62).

Changes in dyspnea score, TLC, FVC, PaO<sub>2</sub>, O<sub>2</sub> saturation, or AaPo<sub>2</sub> over 6 and 12 months may be useful as surrogate endpoints in monitoring therapeutic efficacy in individual patients. Predictor models based on combining multiple baseline clinical, radiologic, or physiologic measurements have been derived from large groups of carefully selected patients with IPF and appear to perform well as predictors of outcome (60, 61).

## NSIP

It is uncertain whether NSIP is a specific separate entity. However, its recognition and separation from UIP has had a major impact on our understanding of the IIPs. Before 1994, the NSIP pattern was included in the histologic spectrum of “UIP” (i.e., called “cellular interstitial pneumonia,” “mixed cellular and fibrotic UIP”). Recent review of the cellular and mixed cases showed most of them to be examples of NSIP. Most important, the identification of NSIP has prognostic significance (see Figure 2). In addition, NSIP (not UIP) is most often found on lung biopsy in patients with connective tissue disease, and may be the pattern identified in some cases of drug-induced lung disease and HP.

NSIP is characterized by varying degrees of inflammation and fibrosis, with some forms being primarily inflammatory (cellular NSIP) and others primarily fibrotic (fibrotic NSIP) (63). Most investigators believe that cellular NSIP is the early stage of fibrotic NSIP. Although NSIP may have significant fibrosis, it is usually of uniform temporality, and fibroblastic foci and honeycombing, if present, are rare. The temporal uniformity is distinctly different from that seen in UIP. Nonetheless, fibrotic NSIP can be difficult to distinguish from UIP, even among expert pathologists.

When lung tissue is obtained from multiple sites, an NSIP-like pattern is sometimes found in association with another histopathologic pattern, particularly UIP. To date, there have been no reports documenting progression from NSIP to UIP (or vice versa). As Katzenstein and coworkers (64) have stated, for NSIP (a uniform process with minimal architectural destruction) to evolve into UIP (a nonuniform process with alternating zones of dense fibrosis, fibroblast foci, scant inflammation, normal lung, and honeycomb change), one would have to postulate that some

TABLE 5. AMERICAN THORACIC SOCIETY/EUROPEAN RESPIRATORY SOCIETY CRITERIA FOR DIAGNOSIS OF IDIOPATHIC PULMONARY FIBROSIS IN ABSENCE OF SURGICAL LUNG BIOPSY

### Major criteria

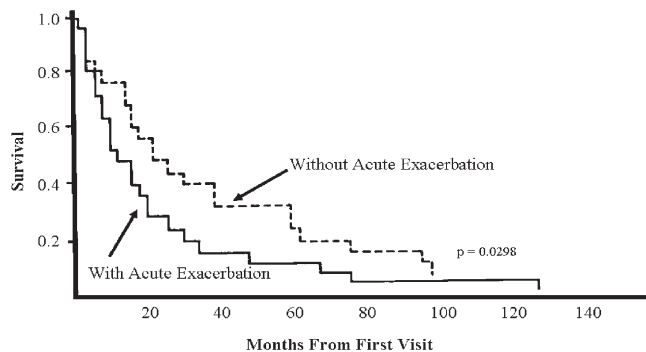
- Exclusion of other known causes of ILD, such as certain drug toxicities, environmental exposures, and connective tissue diseases
- Abnormal pulmonary function studies that include evidence of restriction (reduced VC, often with an increased FEV<sub>1</sub>/FVC ratio) and impaired gas exchange (increased P[A–a]O<sub>2</sub>, decreased PaO<sub>2</sub> with rest or exercise or decreased DL<sub>CO</sub>)
- Bibasilar reticular abnormalities with minimal ground glass opacities on HRCT scans
- Transbronchial lung biopsy or BAL showing no features to support an alternative diagnosis

### Minor criteria

- Age > 50 yr
- Insidious onset of otherwise unexplained dyspnea on exertion
- Duration of illness > 3 mo
- Bibasilar, inspiratory crackles

Definition of abbreviations: BAL = bronchoalveolar lavage; DL<sub>CO</sub> = diffusing capacity of the lung for carbon monoxide; HRCT = high-resolution computed tomography; ILD = interstitial lung disease; P(A–a)O<sub>2</sub> = alveolar-arterial pressure difference for oxygen; VC = vital capacity.

In the immunocompetent adult, the presence of all of the major diagnostic criteria as well as at least three of the four minor criteria increases the likelihood of a correct clinical diagnosis of idiopathic pulmonary fibrosis. Reprinted by permission from Reference 28.



**Figure 3.** Comparison of the survival curves in patients with idiopathic interstitial pneumonia and without acute exacerbation. Without acute exacerbation ( $n = 39$ ; mean survival time = 35.2 months, 50% survival = 19.7 months). With acute exacerbation ( $n = 84$ ; mean survival time = 21.8 months, 50% survival = 11.2 months). In the vast majority of cases, acute exacerbation occurred once during the entire course of the disease. Redrawn by permission from Reference 58.

of the involved areas in NSIP revert to normal, whereas others progress to irreversible fibrosis and honeycomb change. One explanation for the coexistence of NSIP-like areas and UIP is that two different mechanisms of fibrosis are occurring. Conceivably, the initial injury in UIP could itself cause secondary inflammation and fibrosis that resemble NSIP, thus explaining the finding of NSIP-like areas in UIP (64). This problem is further confounded by sampling problems at the time of biopsy—that is, the usually isolated areas of NSIP may in fact be a homogeneous area in what is more macroscopically UIP (and clinically behaves like IPF) but only the NSIP was sampled. More specific criteria or the development of precise molecular markers therefore are needed to accurately distinguish these two histopathologic patterns. In this regard, this emphasizes the vital role of clinical, radiologic, histopathologic correlation in clarifying such apparent inconsistencies (21, 22). Importantly, in cases where UIP and NSIP coexist in the same lung specimen, the clinical behavior of the patient is most consistent with that of UIP—that is, UIP injury is the dominant factor controlling prognosis and treatment responsiveness (65).

### Cryptogenic Organizing Pneumonia

Foci of organizing pneumonia are commonly found at surgical lung biopsy in many settings (e.g., postinfectious, malignancy, drug-related lung injury, connective tissue disease–related, post-transplant, aspiration, inflammatory bowel disease), and even associated with other IIPs, including UIP. However, in 1983, Davison and coworkers (66) described a clinicopathologic entity of isolated organizing pneumonia in patients without an identifiable associated disease. In 1985, Epler and colleagues (67) described the same entity under the term bronchiolitis obliterans organizing pneumonia, and that latter term came into common usage. The ATS/ERS consensus statement recommended that the term cryptogenic organizing pneumonitis be used because it conveys the essential features of the syndrome described below and avoids confusion with airway diseases such as constrictive bronchiolitis obliterans (22).

**Diagnosis.** The clinical presentation of cryptogenic organizing pneumonia can be mistaken for community-acquired pneumonia or ILD, depending on the duration and constellation of presenting symptoms (Table 3). HRCT scanning is distinctive and reveals a predominance of bilateral, patchy consolidation, most commonly with a subpleural or peribronchial distribution. Peri-

bronchovascular nodules (occasionally quite large) and irregular linear, subpleural opacities are also seen. Ground-glass opacities may occasionally be prominent findings. Honeycombing is rarely, if ever, present.

The histopathologic appearance of organizing pneumonia is a uniform temporal appearance of mild interstitial chronic inflammation associated with an intraluminal organizing fibrosis in distal airspaces (bronchioles, alveolar ducts, and alveoli). The lung architecture is generally well preserved, and honeycombing is not described.

**Treatment.** A remarkable feature of the “fibrosis” of cryptogenic organizing pneumonia is that it is usually steroid responsive: more than 80% of patients will improve or return to normal. With treatment, the 5-year survival approaches 100%. However, recurrence (usually after withdrawal of steroids) can be quite common and may be life-threatening.

### Smoking-related ILD

A number of ILDs are linked to cigarette smoking: pulmonary Langerhans’ cell histiocytosis, DIP, RB-ILD, IPF, rheumatoid arthritis–associated ILD, and acute eosinophilic pneumonia (68). DIP and RB-ILD may be manifestations of the same condition. In fact, respiratory bronchiolitis is found in any lung biopsy from a smoker. The most striking feature of these two conditions is the filling of alveoli by pigment-laden macrophages.

### THERAPY FOR IIPs

A major problem has been the lack of large, randomized clinical trials to guide treatment of these diseases. Multiple reasons exist for the paucity of clinical trials: the number of patients is limited and an adequate trial would require multiple centers to recruit sufficient numbers of patients, there is a lack of consensus regarding the diagnostic criteria and outcome variables, there are few new therapies ready for evaluation, and there is a general concern that controlled trials including a placebo arm are unethical in view of the poor prognosis of untreated cases and evidence of “response to steroids” in retrospective studies.

### Treatment of IPF

Conventional management of IPF has been based on the concept that suppressing inflammation would prevent progression to fibrosis. Untreated patients invariably progress. Corticosteroids have been the mainstay of therapy since their initial release for clinical use in 1948; however, few controlled clinical trials have been performed. Using the current diagnostic criteria, there have been no or poor response rates (8–17%) to corticosteroids for patients with UIP.

Azathioprine or cyclophosphamide alone or in combination with corticosteroids showed limited efficacy and frequent adverse effects in patients with IPF. A number of other drug combinations have been tried with prednisone (e.g., methotrexate, colchicine, penicillamine, or cyclosporine) but have failed or are not well tolerated by patients (69). Currently, there is no good evidence to support the routine use of any specific therapy in the management of IPF (56, 70, 71). Initial studies suggest that IFN- $\gamma$ 1b may delay progression of disease or improve survival in patients with less impaired lung function at presentation. However, IFN- $\gamma$ 1b has no effect in patients with severe impairment (FVC, < 55%, or diffusion capacity for the lung for carbon monoxide, < 30% of predicted) (56, 57, 72). Pirfenidone may improve lung function and reduce the number of episodes of acute exacerbation of IPF (71). The addition of N-acetylcysteine to standard therapy (prednisone and azathioprine) appeared to slow the progression of IPF compared with patients given standard therapy alone. Additional large clinical trials are needed

to confirm these preliminary findings regarding the potential usefulness of IFN, pirfenidone, or acetylcysteine.

### Treatment of Other IIPs

Retrospective reviews suggest a clinical response to corticosteroids in 16 to 57% of patients with IIPs (other than UIP and acute interstitial pneumonia). Importantly, these studies did not distinguish between histopathologic subgroups and relied on the clinical diagnosis (not biopsy confirmed) of IIP in the majority of patients. We believe, based on reviews of the cases from many of these studies, that the treatment-responsive patients were mostly cases of NSIP, DIP, RB-ILD, or cryptogenic organizing pneumonia, not UIP. There are no prospective treatment studies for NSIP, DIP, or RB-ILD. However, retrospective reviews of observational studies in which most patients received corticosteroids alone or in combination with azathioprine or cyclophosphamide have suggested excellent responsiveness for NSIP, cryptogenic organizing pneumonia, and DIP (73). RB-ILD appears to resolve in most patients after smoking cessation alone.

### Lung Transplantation

In the late 1980s, single lung transplantation was introduced as a treatment of last resort for patients with progressive lung fibrosis (74). It improves survival but has considerable problems in its own right. Unfortunately, patients with IIP are often referred too late—30% or more die while on the waiting list. It has been found that several ILDs recur in the recipient lung, including LAM, sarcoidosis, Langerhans' cell histiocytosis, idiopathic pulmonary hemosiderosis, pulmonary alveolar proteinosis, giant cell interstitial pneumonitis, talc granulomatosis, and DIP.

## SARCOIDOSIS

Sarcoidosis, a worldwide phenomenon, is a systemic disorder of unknown origin characterized by granulomatous inflammation

in a variety of organs, most commonly the lung (75). The medical history of sarcoidosis is interesting and has been recently reviewed (11, 76). Table 6 shows many of the important milestones in diagnosis and management of sarcoidosis. After its initial description in the late 1800s, sarcoid was assumed to be a primarily dermatologic process with uncommon involvement limited to a specific site (e.g., ocular, parotid glands, bones). Around 1900, Boeck introduced the term *sarkoid* because he believed that the lesions resembled sarcoma, but were benign (76). Over the next decade, the systemic nature of the disorder became well recognized. Worldwide mass chest radiographic surveys among armed forces recruits during World War II called attention to the importance of silent bilateral hilar adenopathy. This led to recognition that asymptomatic cases far outnumber symptomatic cases and helped distinguish sarcoidosis from tuberculosis. From the 1950s to 1980s, studies dissected the epidemiology and immunologic, biochemical, and pathogenetic mechanisms.

### Diagnosis

Histologic confirmation of the presence of granulomas is critical in the diagnosis of sarcoid. In addition, the chest x-ray played an important role in diagnosis and a large literature exists. The exact role of CT in the diagnosis remains poorly defined (11, 75). Magnetic resonance imaging is used to show evidence of sarcoidosis in a particular organ, including neurologic, muscle, and bone disease. Contrast enhancement with gadolinium improves the sensitivity of the technique. Positron emission tomography scanning with various markers has shown usefulness in the detection of occult disease activity (75).

### Etiology and Pathogenesis of Sarcoidosis

The cause is not known. Advances made during the last three decades establish several lines of evidence supporting the hypothesis that sarcoidosis results from exposure of genetically susceptible hosts to specific environmental agents (11). Sarcoido-

TABLE 6. MILESTONES IN DIAGNOSIS AND MANAGEMENT OF SARCOIDOSIS

Date	Milestones
1869–1877	Hutchinson: first account of patient with skin lesions Carl Boeck: provided drawings of skin lesions
1889	Besnier: coined term "lupus pernio"
1892	Tenneson: defined histologic features of lupus pernio
1897–1899	Caesar Boeck: skin lesions, lymphadenopathy, and histology
1904	Kreibich: bone changes
1909–1910	Schumaker, Heerfordt, Bering: uveoparotid fever
1915	Kuzbutsky and Bittorf: involvement of internal organs with enlarged hilar nodes, and pulmonary infiltrates on chest radiographs Schaumann: described multisystem disorder
1937	Waldenstrom: uveoparotid fever
1939	Harrell and Fisher: hypercalcemia and hypercalciuria first observed
1941	Kveim: observed that intradermal inoculation of sarcoid lymph node tissue elicited a popular eruption in patients with sarcoidosis
1946	Lofgren: delineated a syndrome characterized by erythema nodosum, bilateral hilar lymphadenopathy, fever, and polyarthritis
1951	Sones and colleagues: corticosteroids were first used to treat sarcoidosis
1952–1967	Necropsy studies and a large clinical series further defined the clinical spectrum and natural history of sarcoidosis
1958	Wurm and colleagues proposed radiographic staging system
1958	First International Meeting on Sarcoidosis was convened by Geraint James in London
1961	Siltzbach: developed a revised Kveim test using splenic suspension, affirmed its specificity, and organized an international study (Kveim-Siltzbach Test)
1963	International Committee on Sarcoidosis formed to develop a wider base for research and epidemiologic studies
1975	Seventh International Conference in New York: immunological aberrations associated with sarcoidosis were defined and serum angiotensin-converting enzyme was first recognized as a possible biochemical marker of active sarcoidosis
1970s–1980s	Studies dissected the immunologic, biochemical, and pathogenetic mechanisms
1984	The journal <i>Sarcoidosis</i> started in Milan by Gianfranco Rizzato
1987	World Association of Sarcoidosis and Other Granulomatous Disorders (WASOG) formed
1980s and 1990s	Compartmentalization of the immune response and involvement of helper T lymphocytes and activated immune effector cells at sites of disease activity were appreciated

Adapted from References 11 and 76.



sis represents an exaggerated Th1-type immune response triggered by an antigen at sites of disease activity (77). Illness among clusters of individuals has suggested that there is person-to-person transmission or shared exposure to an environmental agent. To date, there is no evidence that sarcoidosis is caused by an infectious agent, although several organisms have been implicated (e.g., mycobacteria, viruses, *Borrelia burgdorferi*, and *Propionibacterium acnes*). A role for a transmissible agent is further suggested by the finding of granulomatous inflammation in patients without sarcoidosis who received heart transplantation from donors who had sarcoidosis and in heart and lung allografts in patients who received heart or lungs from donors without sarcoidosis (76). In addition, noninfectious environmental agents can elicit a granulomatous response with many features that are similar to sarcoidosis (e.g., beryllium, aluminum, and zirconium) (11).

Sarcoidosis is genetically a complex disease whose genetic predisposition is determined by the varying effects of several genes. Epidemiologic studies show significant heterogeneity in disease presentation and severity occurs among different ethnic and racial groups. There are numerous reports of familial clustering of sarcoidosis. The most prominent finding is linkage to a section within major histocompatibility complex (MHC) on the short arm of chromosome 6. What is emerging from these studies is that there seems to be several alleles that confer susceptibility to disease (HLA DR 11, 12, 14, 15, 17) and some that seem to be protective (including HLA DR1, DR4, and possibly HLA DQ\*0202) (75).

#### Treatment of Patients with Sarcoidosis

The treatment of patients with sarcoidosis remains controversial (11, 75). There are specific instances when treatment is critical, such as with cardiac or eye involvement. However, for many patients, systemic treatment is not necessary. There is a growing belief that corticosteroid treatment can lead to a chronic fibrotic form of the disease. Whether the risks associated with long-term corticosteroids are worth the modest benefit seen in the few well-designed clinical trials remains unclear. The use of methotrexate, azathioprine, and hydroxychloroquine as second-line agents has become the standard for most patients with symptomatic sarcoidosis who develop unacceptable side effects of corticosteroid therapy (11, 75). There is particular interest in matching of the treatment with the various biochemical and molecular changes found in the disease. In particular, tumor necrosis factor- $\alpha$  has been investigated because it was shown that alveolar macrophages retrieved by BAL release large amounts of tumor necrosis factor  $\alpha$ , the levels fall with treatment, and this is predictive for persistent disease. Consequently, tumor necrosis factor- $\alpha$  modifiers, including pentoxifylline, thalidomide, etanercept, and infliximab, are under investigation (75).

#### LAM

LAM is a rare multisystem disease of premenopausal women, characterized by cystic degeneration of the lungs, renal angiomyolipomas, and lymphatic lesions ( $\sim 3\text{--}5/1,000,000$  women) (78). LAM was first described in 1937 by German and English investigators who termed the lesions "muscular cirrhosis" and "leiomyosarcoma" of the lung. In 1970, Japanese researchers reported a series of cases that increased interest in the disease. Subsequently, it became apparent that the common feature was the presence of smooth muscle proliferations in the lung. LAM is the prototypic example of the value of national registries for patients with rare diseases. Volunteer national registries in the United States, France, and Japan have been important resources to obtain data and to promote research on the disease (78).

#### Diagnosis

LAM is often misdiagnosed as asthma or chronic obstructive pulmonary disease. LAM occurs as an isolated disorder or in association with tuberous sclerosis complex (TSC; affecting approximately one-third of women). TSC is an autosomal dominant disorder involving hamartomas in multiple organs. Progress has been made in our understanding of the molecular and cellular mechanisms that underlie LAM.

There is evidence for the colocalization of estrogen and progesterone receptors in LAM cells. LAM cells differ from normal smooth muscle cells by the presence of gp100, a 100-kD glycoprotein found in melanoma that reacts with a monoclonal antibody, HMB45. In addition, LAM lesions are marked by proliferation of abnormal-appearing smooth muscle-like cells that have loss of heterozygosity and inactivating mutations in one of the two TSC genes. Most mutations have been described in the TSC2 (16p13) gene (a tumor suppressor gene implicated in TSC), with mutations in the TSC1 gene (9q34) being less frequent (79). In LAM lung lesions, loss of heterozygosity or other somatic mutations in either TSC gene have been reported. It has been shown that renal angiomyolipomas contain abnormal smooth muscle-like LAM cells, blood vessels, and adipose cells. All three types of angiomyolipomas cells appear to be neoplastic, based on loss of heterozygosity as the second genetic hit. Loss of heterozygosity at the TSC2 locus has also been detected in lymph nodes from a transplant patient with LAM. Recurrent LAM cells within donor lungs after transplantation were of recipient origin, suggesting metastatic spread. These "neoplastic" LAM cells have been identified in the blood and other body fluids of patients with LAM (80).

#### Treatment

Progression is common, with a median survival of 8 to 10 years from diagnosis. Estrogen-containing medications should be discontinued. Oophorectomy, progesterone, tamoxifen, and luteinizing hormone-releasing hormone analogs have been used with limited success. Lung transplantation offers the only hope for cure despite reports of recurrent disease in the transplanted lung.

### OCCUPATIONAL AND ENVIRONMENTAL LUNG DISEASE

#### Pneumoconioses

The industrial revolution of the 19th century resulted in widespread exposure to the inhalation of dust that promoted the development of diseases with significant morbidity and mortality, with asbestos and silicosis being the most prevalent pneumoconioses. Epidemiologic studies identified a myriad of causes and established links between the extent of exposure and the risk of developing ILD. These studies led to improved working conditions, dust control measures, and more stringent regulations, which resulted in a decrease in the incidence of severe forms of silicosis, coal worker pneumoconiosis, and asbestosis (especially in industrialized countries). Importantly, pneumoconioses are still a common cause of chronic lung diseases; however, as the classic mineral dust-induced pneumoconioses decrease in frequency, obstructive airway diseases have emerged as the most prevalent category of occupational respiratory disorder (81). The diversity of settings in which many of these agents (especially silica and asbestos) are used continues to add new cases, and thus the burden of disease related to remote and ongoing exposures is still considerable (82).

Overall, the clinical picture of the classic pneumoconioses and their complications has not changed substantially. However, advances in lung imaging, mineralogic analysis of BAL fluid,

immunologic techniques, and lung biopsy (in selected cases) have been instrumental in early detection (often before symptoms or lung function abnormalities are detected) and have identified new patterns of disease (82).

Over the past 20 to 30 years, an increase in industrial processes has led to the production and use of large numbers of chemicals, metals, and alloys. Increasingly, many of these newer substances or exposures are being reported as causes of ILD (e.g., beryllium, polyvinylchloride, exposure to paint (aerograph) aerosol in the textile industry, nylon flock, organic vapors from flavorings). In many of the newly recognized diseases, the traditional dose-effect relationships often do not apply.

## HP

**Diagnosis.** HP is caused by inhalation of many different environmental antigens. The prevalence of HP is higher than recognized, especially its chronic form. Genetic variations determine individual susceptibility to lung disease. Mechanisms of disease are still incompletely known; however, recent advances have revealed that HP is a complex syndrome of varying intensity, clinical presentation, and natural history rather than a single, uniform disease (83, 84). Numerous agents have been described, including, but not limited to, agricultural dusts, bioaerosols, microorganisms (fungal, bacterial, nontuberculous mycobacteria, or protozoal), and certain reactive chemical species. Because of effective preventive measures in the workplace, HP occurs predominantly from domestic exposures, and bird allergens constitute the majority of the causative agents.

The presence or absence of serum precipitins is of limited usefulness in the diagnosis of HP. However, serum precipitins may be useful to identify the causative agent once the diagnosis has been established. Widespread use of HRCT and improved recognition of the patterns suggestive of HP has broadened the identification of cases and the search for potential cause, especially in sporadic cases. The HRCT pattern can be variable depending on the stage of disease, but characteristically, it shows a mid- to upper zone predominance of centrilobular ground-glass or nodular opacities with signs of air-trapping. A presumptive diagnosis of HP can be established even without the identification of the source of exposure in the proper clinical setting.

**Treatment.** Antigen avoidance is the key element in the treatment of HP. Often, there is a beneficial response to corticosteroids. However, it can be difficult to distinguish between the effects of treatment and the natural course of the disease. A randomized, double-blind, placebo-controlled study of corticosteroids in patients with acute farmer's lung found that patients given prednisolone showed more rapid improvement in lung function but there was no difference in the long-term outcome between the two groups (85). Recurrences were more common among corticosteroid-treated patients than among control subjects if they had continuing antigen exposure, raising the possibility that treatment suppressed important regulatory aspects of the immune response in these patients. Farmer's lung is not a benign disease; approximately 50% of farmers develop chronic lung impairment, commonly with obstructive abnormalities often associated with emphysematous changes on HRCT. Bird fancier's lung may have a worse prognosis compared with other exposures. HP is characterized by several histologic patterns of lung injury (in combination or alone). A recent workshop has recommended several areas for additional investigation (86).

## CONCLUSIONS

Much has been learned over the last 100 years. At times, progress was slowed by strongly held beliefs in things we did not understand, inattention to progress made in other fields and its poten-

tial application to ours, inability to perform adequate clinical trials, and a failure to communicate and collaborate. Until recently, the level of evidence in support of most recommendations regarding diagnosis and treatment was largely that of expert opinion developed by consensus. We have made tremendous progress and have entered a new era in the understanding of the classification, pathogenesis, and biology of ILDs. With support from our professional organizations, governmental agencies, and industry, we have organized consensus conferences and working groups, established registries, and, most important, begun large multicenter clinical trials. Technological advances and the development of animal models have had a major impact on understanding the pathogenesis and potential molecular targets for interfering with fibrogenesis. The recent decision by the NHLBI to establish a national IPF Clinical Research Network (to conduct coordinated clinical and laboratory studies of well-characterized patients and patient-derived materials) is an exciting development. These efforts will soon lead to therapies that are more effective for our patients.

**Conflict of Interest Statement:** T.E.K. has been involved in Scientific Advisory Boards for Actelion, InterMune, Nektar, and GlaxoSmithKline. He has served as a consultant for Alexza, AstraZeneca, Biogen, Centocore, Fibrogen, Genzyme, Human Genome Sciences, Merck, and CoTherix.

## References

- Lloyd JE. Pulmonary fibrosis in families. *Am J Respir Cell Mol Biol* 2003;29:S47-S50.
- Wells AU. Lung disease in association with connective tissue diseases. *Eur Respir Mon* 2000;14:137-164.
- Schwarz MI, King TE Jr. Interstitial lung diseases, 4th ed. Hamilton, ON, Canada: B.C. Decker; 2003.
- Travis WD, Colby TV, Koss MN, Müller NL, Rosado-de-Christenson M, King TE Jr. Non-neoplastic disorders of the lower respiratory tract. Washington, DC: Armed Forces Institute of Pathology and American Registry of Pathology; 2002.
- Seymour JF, Presneill JJ. Pulmonary alveolar proteinosis: progress in the first 44 years. *Am J Respir Crit Care Med* 2002;166:215-235.
- Alberts WM. Eosinophilic interstitial lung disease. *Curr Opin Pulm Med* 2004;10:419-424.
- Collard HR, Schwarz MI. Diffuse alveolar hemorrhage. *Clin Chest Med* 2004;25:583-592.
- Vassallo R, Ryu JH, Schroeder DR, Decker PA, Limper AH. Clinical outcomes of pulmonary Langerhans'-cell histiocytosis in adults. *N Engl J Med* 2002;346:484-490.
- Camus P. Drug-induced infiltrative lung disease. In: Schwarz MI, King TE Jr, editors. Interstitial lung diseases, 4th ed. Hamilton, ON, Canada: B.C. Decker; 2003. pp. 485-534.
- Coultas DB, Hubbard R. Epidemiology of idiopathic pulmonary fibrosis. In: Lynch JP III, editor. Idiopathic pulmonary fibrosis, lung biology in health and disease. New York: Marcel Dekker; 2004. p. 772.
- American Thoracic Society Statement on sarcoidosis. *Am J Respir Crit Care Med* 1999;160:736-755.
- Austrian R, McClement JH, Renzetti AD Jr, Donald KW, Riley RL, Courmand A. Clinical and physiologic features of some types of pulmonary diseases with impairment of alveolar capillary diffusion: the syndrome of "alveolar-capillary blocks." *Am J Med* 1951;11:667-685.
- Finley TN, Swenson EW, Comroe JH Jr. The cause of arterial hypoxemia at rest in patients with "alveolarcapillary block syndrome." *J Clin Invest* 1962;41:618-622.
- Wagner PD, Dantzker DR, Dueck R, dePolo JL, Wasserman K, West JB. Distribution of ventilation-perfusion ratios in patients with interstitial lung disease. *Chest* 1976;69:256-257.
- Fulmer JD, Roberts WC, von Gal ER, Crystal RG. Morphologic-physiologic correlates of the severity of fibrosis and degree of cellularity in idiopathic pulmonary fibrosis. *J Clin Invest* 1979;63:665-676.
- Watters LC, King TE, Schwarz MI, Waldron JA, Stanford RE, Cherniack RM. A clinical, radiographic, and physiologic scoring system for the longitudinal assessment of patients with idiopathic pulmonary fibrosis. *Am Rev Respir Dis* 1986;133:97-103.
- Cherniack RM, Colby TV, Flint A, Thurlbeck WM, Waldron JA Jr, Ackerson L, Schwarz MI, King TE Jr. Correlation of structure and

- function in idiopathic pulmonary fibrosis. *Am J Respir Crit Care Med* 1995;151:1180-1188.
18. Hanley ME, King TE Jr, Schwarz MI, Watters LC, Shen AS, Cherniack RM. The impact of smoking on mechanical properties of the lungs in idiopathic pulmonary fibrosis and sarcoidosis. *Am Rev Respir Dis* 1991;144:1102-1106.
  19. Gaensler EA, Moister VB, Hamm J. Open-lung biopsy in diffuse pulmonary disease. *N Engl J Med* 1964;270:1319-1331.
  20. Glaspole IN, Wells AU, du Bois RM. Lung biopsy in diffuse parenchymal lung disease. *Monaldi Arch Chest Dis* 2001;56:225-232.
  21. Flaherty KR, King TE Jr, Raghu G, Lynch JP III, Colby TV, Travis WD, Gross BH, Kazerooni EA, Toews GB, Long Q, et al. Idiopathic interstitial pneumonia: what is the effect of a multidisciplinary approach to diagnosis? *Am J Respir Crit Care Med* 2004;170:904-910.
  22. American Thoracic Society/European Respiratory Society international multidisciplinary consensus classification of the idiopathic interstitial pneumonias. *Am J Respir Crit Care Med* 2002;165:277-304.
  23. Andersen HA. Transbronchoscopic lung biopsy for diffuse pulmonary diseases: results in 939 patients. *Chest* 1978;73:734-736.
  24. Wall CP, Gaensler EA, Carrington CB, Hayes JA. Comparison of transbronchial and open biopsies in chronic infiltrative lung diseases. *Am Rev Respir Dis* 1981;123:280-285.
  25. Katzenstein AL, Askin FB. Interpretation and significance of pathologic findings in transbronchial lung biopsy. *Am J Surg Pathol* 1980;4:223-234.
  26. Poletti V, Patelli M, Poggi S, Bertanti T, Spiga L, Ferracini R. Transbronchial lung biopsy and bronchoalveolar lavage in diagnosis of diffuse infiltrative lung diseases. *Respiration (Herrlisheim)* 1988;54:66-72.
  27. Milman N, Faurschou P, Munch EP, Grode G. Transbronchial lung biopsy through the fibre optic bronchoscope: results and complications in 452 examinations. *Respir Med* 1994;88:749-753.
  28. American Thoracic Society. Idiopathic pulmonary fibrosis: diagnosis and treatment. International consensus statement: American Thoracic Society and the European Respiratory Society. *Am J Respir Crit Care Med* 2000;161:646-664.
  29. Reynolds HY. Use of bronchoalveolar lavage in humans: past necessity and future imperative. *Lung* 2000;178:271-293.
  30. Baughman RP. Bronchoalveolar lavage. St. Louis, MO: Mosby Year Book; 1992.
  31. Wittam C, Mark EJ, McLoud TC. CT-histologic correlation of the ATS/ERS 2002 classification of idiopathic interstitial pneumonias. *Radiographics* 2003;23:1057-1071.
  32. Hunninghake G, Zimmerman MB, Schwartz DA, King TE Jr, Lynch J, Hegele R, Waldron J, Colby T, Muller N, Lynch D, et al. Utility of lung biopsy for the diagnosis of idiopathic pulmonary fibrosis. *Am J Respir Crit Care Med* 2001;164:193-196.
  33. Aziz ZA, Wells AU, Hansell DM, Bain GA, Copley SJ, Desai SR, Ellis SM, Gleeson FV, Grubnic S, Nicholson AG, et al. HRCT diagnosis of diffuse parenchymal lung disease: inter-observer variation. *Thorax* 2004;59:506-511.
  34. Singh S, Wells AU, Du Bois RM. Other imaging techniques for idiopathic interstitial pneumonias. In: Lynch JP III, editor. Idiopathic pulmonary fibrosis. New York: Marcel Dekker; 2004. pp. 237-252.
  35. Hamman L, Rich AR. Acute diffuse interstitial fibrosis of the lungs. *Bull Johns Hopkins Hosp* 1944;74:177-212.
  36. Scadding JG. Chronic diffuse interstitial fibrosis of the lungs. *BMJ* 1960;1:443-450.
  37. Scadding JG, Hinson KFW. Diffuse fibrosing alveolitis (diffuse interstitial fibrosis of the lungs): correlation of histology at biopsy with prognosis. *Thorax* 1967;22:291-304.
  38. Liebow AA, Carrington DB. The interstitial pneumonias. In: Simon M, Potchen EJ, LeMay M, editors. Frontiers of pulmonary radiology. New York: Grune & Stratteon; 1969. pp. 102-141.
  39. Scadding JG. Diffuse pulmonary alveolar fibrosis. *Thorax* 1974;29:271-281.
  40. Crystal RG, Fulmer JD, Roberts WC, Moss ML, Line BR, Reynolds HY. Idiopathic pulmonary fibrosis: clinical, histologic, radiographic, physiologic, scintigraphic, cytologic and biochemical aspects. *Ann Intern Med* 1976;85:769-788.
  41. Katzenstein ALA, Myers JL. Idiopathic pulmonary fibrosis: clinical relevance of pathologic classification. *Am J Respir Crit Care Med* 1998;157:1301-1315.
  42. British Thoracic Society. The diagnosis, assessment and treatment of diffuse parenchymal lung disease in adults. *Thorax* 1999;54:S1-S28.
  43. Selman M, King TE Jr, Pardo A. Idiopathic pulmonary fibrosis: prevailing and evolving hypotheses about its pathogenesis and implications for therapy. *Ann Intern Med* 2001;134:136-151.
  44. Douglas WW, Tazelaar HD, Hartman TE, Hartman RP, Decker PA, Schroeder DR, Ryu JH. Polymyositis-dermatomyositis-associated interstitial lung disease. *Am J Respir Crit Care Med* 2001;164:1182-1185.
  45. Bouros D, Wells AU, Nicholson AG, Colby TV, Polychronopoulos V, Pantelidis P, Haslam PL, Vassilakis DA, Black CM, du Bois RM. Histopathologic subsets of fibrosing alveolitis in patients with systemic sclerosis and their relationship to outcome. *Am J Respir Crit Care Med* 2002;165:1581-1586.
  46. Fujita J, Yoshinouchi T, Ohtsuki Y, Tokuda M, Yang Y, Yamadori I, Bandoh S, Ishida T, Takahara J, Ueda R. Non-specific interstitial pneumonia as pulmonary involvement of systemic sclerosis. *Ann Rheum Dis* 2001;60:281-283.
  47. Kim DS, Yoo B, Lee JS, Kim EK, Lim CM, Lee SD, Koh Y, Kim WS, Kim WD, Colby TV, et al. The major histopathologic pattern of pulmonary fibrosis in scleroderma is nonspecific interstitial pneumonia. *Sarcoidosis Vasc Diffuse Lung Dis* 2002;19:121-127.
  48. Nakamura Y, Chida K, Suda T, Hayakawa H, Iwata M, Imokawa S, Tsuchiya T, Ida M, Gemma H, Yasuda K, et al. Nonspecific interstitial pneumonia in collagen vascular diseases: comparison of the clinical characteristics and prognostic significance with usual interstitial pneumonia. *Sarcoidosis Vasc Diffuse Lung Dis* 2003;20:235-241.
  49. Tansey D, Wells AU, Colby TV, Ip S, Nikolakoupolou A, du Bois RM, Hansell DM, Nicholson AG. Variations in histological patterns of interstitial pneumonia between connective tissue disorders and their relationship to prognosis. *Histopathology* 2004;44:585-596.
  50. Cottin V, Thivolet-Bejui F, Reynaud-Gaubert M, Cadranet J, Delaval P, Ternamian PJ, Cordier JF. Interstitial lung disease in amyopathic dermatomyositis, dermatomyositis and polymyositis. *Eur Respir J* 2003;22:245-250.
  51. Daniele RP, Henson PM, Fantone JC III, Ward PA, Dreisin RB. Immune complex injury of the lung. *Am Rev Respir Dis* 1981;124:738-755.
  52. Johkoh T, Müller NL, Cartier Y, Kavanagh PV, Hartman TE, Akira M, Ichikado K, Ando M, Nakamura H. Idiopathic interstitial pneumonias: diagnostic accuracy of thin-section CT in 129 patients. *Radiology* 1999;211:555-560.
  53. Raghu G, Mageto YN, Lockhart D, Schmidt RA, Wood DE, Godwin JD. The accuracy of the clinical diagnosis of new-onset idiopathic pulmonary fibrosis and other interstitial lung disease: a prospective study. *Chest* 1999;116:1168-1174.
  54. Swensen S, Aughenbaugh G, Myers J. Diffuse lung disease: diagnostic accuracy of CT in patients undergoing surgical biopsy of the lung. *Radiology* 1997;205:229-234.
  55. Flaherty KR, Thwaite EL, Kazerooni EA, Gross BH, Toews GB, Colby TV, Travis WD, Mumford JA, Murray S, Flint A, et al. Radiological versus histological diagnosis in UIP and NSIP: survival implications. *Thorax* 2003;58:143-148.
  56. Raghu G, Brown KK, Bradford WZ, Starko K, Noble PW, Schwartz DA, King TE Jr, and the Idiopathic Pulmonary Fibrosis Study Group. A placebo-controlled trial of interferon gamma-1b in patients with idiopathic pulmonary fibrosis. *N Engl J Med* 2004;350:125-133.
  57. King TE Jr, Safran S, Starko KM, Brown KK, Noble PW, Raghu G, Schwartz DA. Analyses of efficacy end points in a controlled trial of interferon- $\gamma$ 1b for idiopathic pulmonary fibrosis. *Chest* 2005;127:171-177.
  58. Kondo A, Saiki S. Acute exacerbation in idiopathic interstitial pneumonia (IIP). In: Harasawa M, Fukuchi Y, Morinari H, editors. Interstitial pneumonia of unknown etiology. Tokyo: University of Tokyo Press; 1989. pp. 33-42. Japan Intractable Diseases Research Foundation Publication No. 27.
  59. Kondoh Y, Taniguchi H, Kawabata Y, Yokoi T, Suzuki K, Takagi K. Acute exacerbation in idiopathic pulmonary fibrosis: analysis of clinical and pathologic findings in three cases. *Chest* 1993;103:1808-1812.
  60. King TE Jr, Tooze JA, Schwarz MI, Brown K, Cherniack RM. Predicting survival in idiopathic pulmonary fibrosis: scoring system and survival model. *Am J Respir Crit Care Med* 2001;164:1171-1181.
  61. Wells AU, Desai SR, Rubens MB, Goh NS, Cramer D, Nicholson AG, Colby TV, du Bois RM, Hansell DM. Idiopathic pulmonary fibrosis: a composite physiologic index derived from disease extent observed by computed tomography. *Am J Respir Crit Care Med* 2003;167:962-969.
  62. King TE Jr, Schwarz MI, Brown K, Tooze JA, Colby TV, Waldron JA Jr, Flint A, Thurlbeck WM, Cherniack RM. Idiopathic pulmonary fibrosis: relationship between histopathologic features and mortality. *Am J Respir Crit Care Med* 2001;164:1025-1032.
  63. Katzenstein AL, Fiorelli RF. Nonspecific interstitial pneumonia/fibrosis: histologic features and clinical significance. *Am J Surg Pathol* 1994;18:136-147.
  64. Katzenstein AL, Zisman DA, Litzky LA, Nguyen BT, Kotloff RM. Usual



- interstitial pneumonia: histologic study of biopsy and explant specimens. *Am J Surg Pathol* 2002;26:1567–1577.
65. Flaherty KR, Travis WD, Colby TV, Toews GB, Kazerooni EA, Gross BH, Jain A, Strawderman RL, Flint A, Lynch JP, *et al*. Histopathologic variability in usual and nonspecific interstitial pneumonias. *Am J Respir Crit Care Med* 2001;164:1722–1727.
  66. Davison AG, Heard BE, McAllister WAC, Turner-Warwick MEH. Cryptogenic organizing pneumonitis. *Q J Med* 1983;52:382–394.
  67. Epler GR, Colby TV, McLoud TC, Carrington CB, Gaensler EA. Bronchiolitis obliterans organizing pneumonia. *N Engl J Med* 1985;312:152–158.
  68. Shorr AF, Scoville SL, Cersovsky SB, Shanks GD, Ockenhouse CF, Smoak BL, Carr WW, Petruccioli BP. Acute eosinophilic pneumonia among US military personnel deployed in or near Iraq. *JAMA* 2004;292:2997–3005.
  69. Davies HR, Richeldi L, Walters EH. Immunomodulatory agents for idiopathic pulmonary fibrosis. *Cochrane Database Syst Rev* 2003;3:CD003134.
  70. Davies HR, Richeldi L. Idiopathic pulmonary fibrosis: current and future treatment options. *Am J Respir Med* 2002;1:211–224.
  71. Azuma A, Nukiwa T, Tsuboi E, Suga M, Abe S, Nakata K, Taguchi Y, Nagai S, Itoh H, Ohi M, *et al*. Double blind, placebo-controlled trial of pirfenidone in patients with idiopathic pulmonary fibrosis. *Am J Respir Crit Care Med* 2005;171:1040–1047.
  72. Kalra S, Utz JP, Ryu JH. Interferon gamma-1b therapy for advanced idiopathic pulmonary fibrosis. *Mayo Clin Proc* 2003;78:1082–1087.
  73. Kondoh Y, Taniguchi H, Yokoi T, Nishiyama O, Ohishi T, Kato T, Suzuki K, Suzuki R. Cyclophosphamide and low-dose prednisolone in idiopathic pulmonary fibrosis and fibrosing nonspecific interstitial pneumonia. *Eur Respir J* 2005;25:528–533.
  74. Grossman RF, Frost A, Zamel N, Patterson GA, Cooper JD, Myron PR, Dear CL, Maurer J. Results of single-lung transplantation for bilateral pulmonary fibrosis. *N Engl J Med* 1990;322:727–733.
  75. Baughman RP, Lower EE, du Bois RM. Sarcoidosis. *Lancet* 2003;361:1111–1118.
  76. James DG, Sharma OP. From Hutchinson to now: a historical glimpse. *Curr Opin Pulm Med* 2002;8:416–423.
  77. Agostini C, Meneghin A, Semenzato G. T-lymphocytes and cytokines in sarcoidosis. *Curr Opin Pulm Med* 2002;8:435–440.
  78. Moss J, editor. LAM and other diseases characterized by smooth muscle proliferation, lung biology in health and disease. New York: Marcel Dekker; 1999.
  79. Smolarek TA, Wessner LL, McCormack FX, Mylet JC, Menon AG, Henske EP. Evidence that lymphangiomyomatosis is caused by TSC2 mutations: chromosome 16p13 loss of heterozygosity in angiomyolipomas and lymph nodes from women with lymphangiomyomatosis. *Am J Hum Genet* 1998;62:810–815.
  80. Crooks DM, Pacheco-Rodriguez G, DeCastro RM, McCoy JP Jr, Wang J-a, Kumaki F, Darling T, Moss J. Molecular and genetic analysis of disseminated neoplastic cells in lymphangioleiomyomatosis. *Proc Natl Acad Sci USA* 2004;101:17462–17467.
  81. American Thoracic Society. American Thoracic Society statement: occupational contribution to the burden of airway disease. *Am J Respir Crit Care Med* 2003;167:787–797.
  82. De Vuyst P, Camus P. The past and present of pneumoconioses. *Curr Opin Pulm Med* 2000;6:151–156.
  83. Lacasse Y, Selman M, Costabel U, Dalphin JC, Ando M, Morell F, Erkinjuntti-Pekkanen R, Muller N, Colby TV, Schuyler M, *et al*. Clinical diagnosis of hypersensitivity pneumonitis. *Am J Respir Crit Care Med* 2003;168:952–958.
  84. Agostini C, Trentin L, Facco M, Semenzato G. New aspects of hypersensitivity pneumonitis. *Curr Opin Pulm Med* 2004;10:378–382.
  85. Kokkarinen JI, Tukiainen HO, Terho EO. Effect of corticosteroid treatment on the recovery of pulmonary function in farmer's lung. *Am Rev Respir Dis* 1992;145:3–5.
  86. Fink JN, Ortega HG, Reynolds HY, Cormier YF, Fan LL, Franks TJ, Kreiss K, Kunkel S, Lynch D, Quirce S, *et al*. Needs and opportunities for research in hypersensitivity pneumonitis. *Am J Respir Crit Care Med* 2005;171:792–798.
  87. Nagai S, Nagao T, Hoshino Y, Hamada K. Heterogeneity of pulmonary fibrosis: interstitial pneumonias and sarcoidosis. *Curr Opin Pulm Med* 2001;7:262–271.
  88. Turner-Warwick M. A perspective view on widespread pulmonary fibrosis. *BMJ* 1974;2:371–376.
  89. Turner-Warwick M, Burrows B, Johnson A. Cryptogenic fibrosing alveolitis: clinical features and their influence on survival. *Thorax* 1980;35:171–180.
  90. Bjraker JA, Ryu JH, Edwin MK, Myers JL, Tazelaar HD, Schroeder DR, Offord KP. Prognostic significance of histopathologic subsets in idiopathic pulmonary fibrosis. *Am J Respir Crit Care Med* 1998;157:199–203.
  91. Hosoda Y, Sasagawa S, Yasuda N. Epidemiology of sarcoidosis: new frontiers to explore. *Curr Opin Pulm Med* 2002;8:424–428.
  92. Moller DR, Chen ES. What causes sarcoidosis? *Curr Opin Pulm Med* 2002;8:429–434.